

Diabetic foot ulcers

A guide to assessment and management

Managing diabetic foot ulcers with specialist care

Your patients with diabetes face challenges every day. We understand how these become your challenges too. Managing long-term conditions involves being able to balance eating, physical activity, medication, and injections. It's a team effort that can involve a lot of resources and a mix of specialist care.

How common are diabetic foot problems?

Diabetic foot problems are among the most serious and costly complications of diabetes. Diabetic foot ulcer (DFU) prevalence data estimates that, annually, foot ulcers develop in 9.1 million to 26.1 million diabetes patients worldwide¹. Other research has shown that more than half of DFUs become infected; and the risk of death for diabetes patients with foot ulcers is 2.5 times

higher than patients without a foot ulcer¹. The rising prevalence of diabetes worldwide has seen an increase in the number of resulting lower limb amputations². Both ulcers and amputations have an enormous impact on people's lives, often leading to reduced independence, social isolation and psychological stress.



Up to one in every four patients with diabetes risk developing a DFU in their lifetime³

Globally, one leg is lost every

20 seconds

as a result of diabetes⁴

Up to

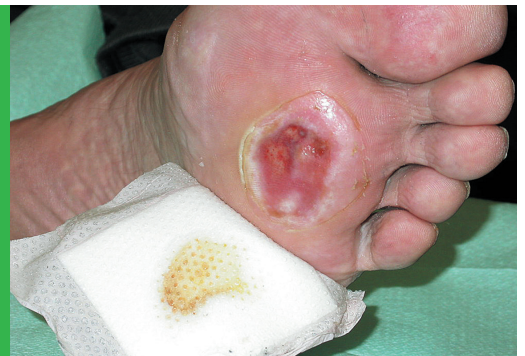80% of

diabetic foot amputations are preceded by a DFU⁵

Up to 85%

of amputations can be avoided when an effective care plan is adopted⁶

Unfortunately, DFU recurrence is common. Roughly 40% of patients have a recurrence within 1 year after ulcer healing, almost 60% within 3 years, and 65% within 5 years¹.



A holistic approach to DFU care

Diabetes is a complex disease. We understand that managing DFUs requires input from a range of specialities throughout the organisation. A multidisciplinary footcare team (MDFT) can provide comprehensive specialist foot and wound care, calling on the expertise of⁷:

- Doctors with a special interest in diabetes
- Podiatrists
- Diabetes specialist nurses
- Infection specialists
- Vascular surgeons
- Orthopaedic surgeons
- Orthotists
- Social workers
- Psychologists

What about your patients' physical, psychological and social health situation? A MDFT's holistic approach is important, not only to focus on evaluating and managing the wound, but diagnosing and treating underlying diseases⁸. By adopting a holistic approach to wound healing, with appropriate referrals and multidisciplinary involvement, DFUs can be healed and lives saved⁷⁻⁹:

Assessment of the patient and the ulcer should include the evaluation of:⁸

- Diabetes, management and blood glucose control
- Previous history of foot ulceration and surgery
- Underlying conditions e.g diabetes renal impairment
- Symptoms and signs of peripheral artery or venous disease
- All sensory, motor and autonomic neuropathy and the need for pressure off-loading
- Systemic signs of infection
- Pain such as neuropathic and/or wound-related pain
- Local wound assessment for appropriate management approach. See page 7-9.
- Socioeconomic circumstances, dexterity, visual acuity and insight
- Smoking status

If a person has a limb-threatening or life-threatening diabetic foot problem, they should be referred immediately to acute services and a MDFT informed. For all other active diabetic foot problems, the person should be referred within 1 working day to a MDFT.¹⁰

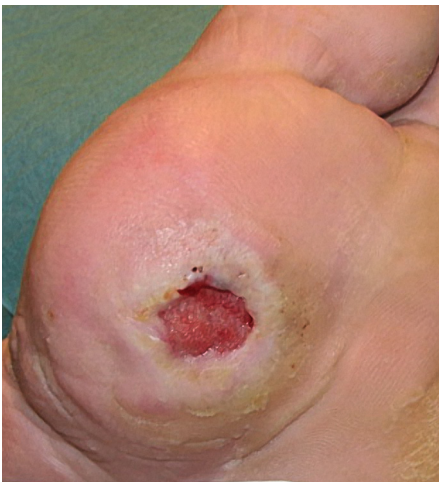What about prevention?

You and your team care about the outcomes for your patients. So prevention strategies make sense as a crucial step in avoiding an ulcer. It's all part of effective foot care – a partnership between you, your patients and their carers.

Appropriate information that enables patients and carers to participate in decision making is often at the heart of all effective prevention strategies. We've heard how your patients like to have an understanding of the rationale behind some of the clinical decisions – it's information that supports good self-care – so we've included patient education and self-care advice on page 10.

Aetiology of diabetic foot ulcers

Did you know there are **three key aetiologies** that influence assessment, treatment of the underlying condition and management of a DFU?

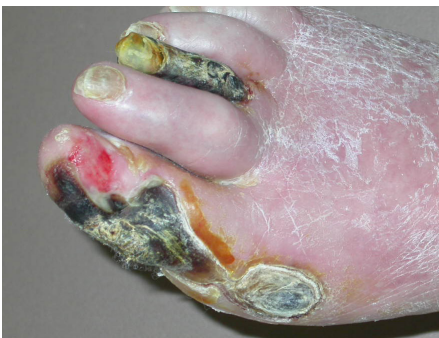

1. Neuropathic foot⁷

- Due to peripheral neuropathy (see below).
- Warm with good blood flow and palpable pedal pulses.
- Ulcer locations are often weight-bearing areas of the foot, such as metatarsal heads, the heel and over the dorsum of clawed toes.
- Wound beds are pink and granulating, surrounded by callus.

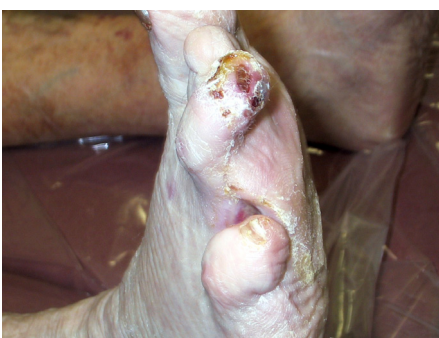The main types of peripheral neuropathy are:

- **Autonomic neuropathy** – loss of perspiration; dry skin that can lead to cracks and callus; increased peripheral blood flow and distended foot veins and a warm, dry foot, which can be misinterpreted as a healthy foot¹¹.
- **Motor neuropathy** – hollow of the foot is unusually curved; toes are bent into a claw, placing abnormal stress on the foot; abnormal pressure over bone prominences. See picture 1 on page 6.
- **Sensory neuropathy** – reduction or loss of protective sensation increases vulnerability to physical, chemical and thermal trauma. Further reading in section 'Testing for loss of sensation' on page 6.



2. Ischaemic foot due to peripheral arterial disease (PAD)⁷

- Due to a dysfunction of large vessels (macroangiopathy) or small vessels (microangiopathy).
- Typically cool with absent pulses.
- Ulcers are often at the tips of the toes, nail edges, between the toes and lateral borders of the foot.
- Wound beds are pale and sloughy with poor granulation. Further reading in section 'Testing for vascular status' on page 6.



3. Neuroischaemic foot⁷

- Due to a combination of neuropathy and ischaemia.
- Typically cool with absent pulses.
- High risk of wound infection.
- Ulcers are often on the margins of the foot and toes.
- Wound beds have poor granulation.

Diabetic foot ulcer classifications

How is your team classifying each wound? Did you know it's important that each wound is classified according to a validated clinical tool⁹? For example:

- Wagner¹²
- University of Texas¹³⁻¹⁴
- PEDIS¹⁵
- SINBAD¹⁶
- Wifl (WiFi)¹⁷

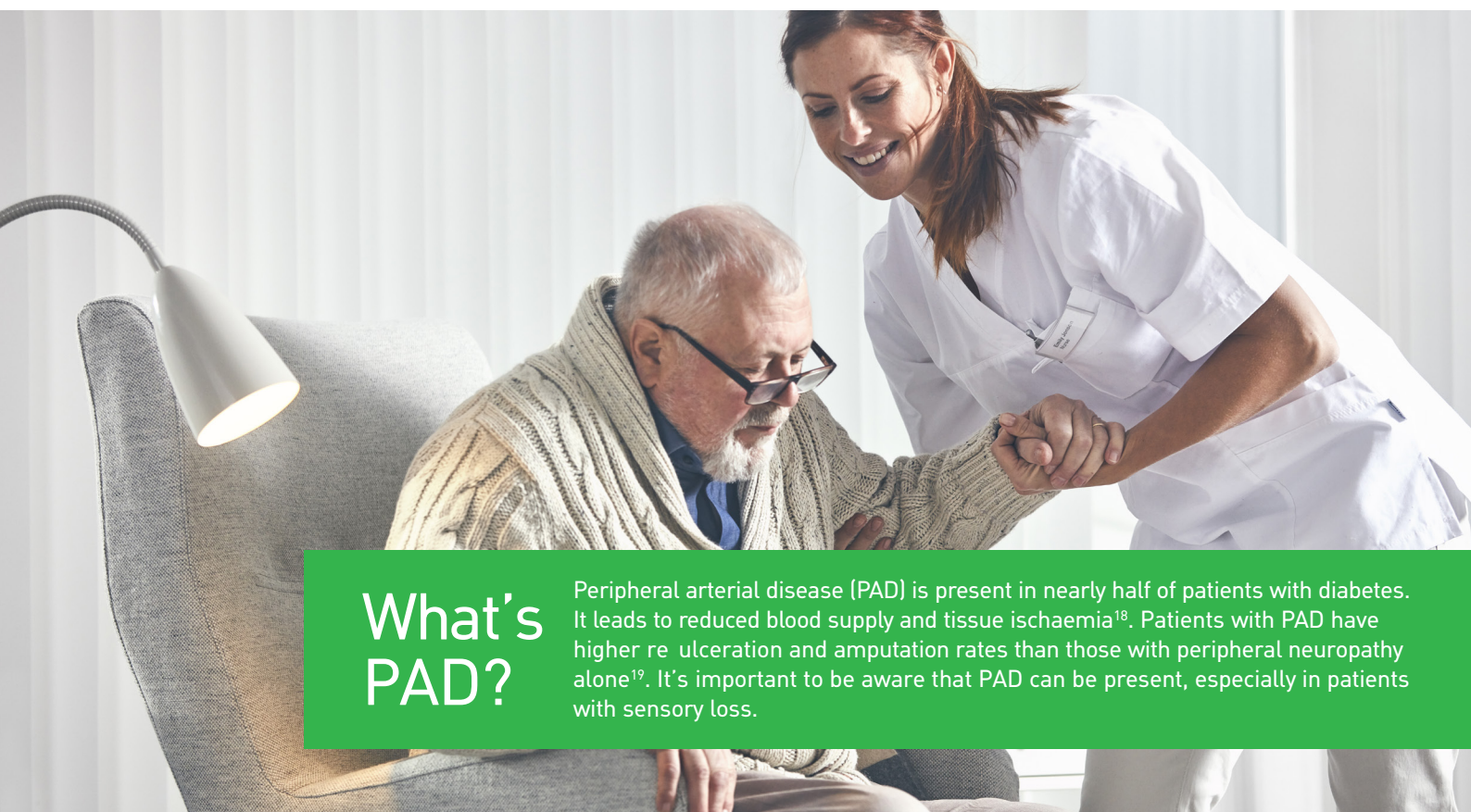Wagner classification of diabetic foot ulcers

Grade 0	No ulcer in a high risk foot
Grade 1	Superficial ulcer involving the full skin thickness but not underlying tissues
Grade 2	Deep ulcer, penetrating down to ligaments and muscle, but no bone involvement or abscess formation
Grade 3	Deep ulcer with cellulitis or abscess formation, often with osteomyelitis
Grade 4	Localised gangrene
Grade 5	Extensive gangrene involving the whole foot

University of Texas classification of diabetic foot ulcers

Ulcer stage	Ulcer grade (depth)			
	0	I	II	III
A	Pre/post ulcerative lesion completely epithelialised	Superficial ulcer, not involving tendon, capsule or bone	Ulcer penetrating to tendon or capsule	Ulcer penetrating to bone or joint
B	Infection	Infection	Infection	Infection
C	Ischaemia	Ischaemia	Ischaemia	Ischaemia
D	Infection and ischaemia	Infection and ischaemia	Infection and ischaemia	Infection and ischaemia

To ensure holistic assessment and treatment of DFUs, the wound should be classified according to a validated clinical tool⁹.



What's PAD?

Peripheral arterial disease (PAD) is present in nearly half of patients with diabetes. It leads to reduced blood supply and tissue ischaemia¹⁸. Patients with PAD have higher re-ulceration and amputation rates than those with peripheral neuropathy alone¹⁹. It's important to be aware that PAD can be present, especially in patients with sensory loss.

A guide to assessing DFUs

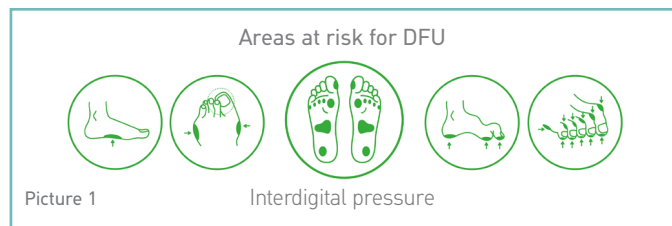✔ Inspecting foot deformities

Excessive or abnormal plantar pressure, resulting from limited joint mobility, often combined with foot deformities, is a common underlying cause of DFUs in individuals with neuropathy³.

Common foot deformities^{7,11}:

- Prominent metatarsal heads
- Hammer toes
- Clawed toes
- A high-arch foot
- Hallux valgus (bunion), hallux rigidus (stiff big toe) and plantar fat pad atrophy
- Charcot deformity (read more below)

Patients also develop atypical walking patterns and this can result in calluses, which increase the abnormal pressure and can cause subcutaneous haemorrhage and ulcers. At the same time with neuropathy and the loss of sensation, the patient continues to walk on the foot, increasing the risk of further problems⁷.



Charcot foot

Charcot foot – Charcot neuropathic osteoarthropathy (CN) – is a condition affecting the bones, joints, and soft tissues of the foot and ankle. In the acute stage, there is inflammation and bone reabsorption, which weakens the bone. In later stages, the arch falls and the foot may develop a ‘rocker-bottom’ appearance. Early treatment with offloading pressure can help stop bone destruction and promote healing⁷.

Typical clinical findings may include²⁰:

- Markedly swollen, warm, and often erythematous foot
- Mild to modest pain or discomfort.
- Acute local inflammation (often the earliest sign of underlying bone and joint surgery).
- The classic ‘rocker-bottom’ foot deformity is a late stage of the symptom.
- Temperature differential of several degrees between feet.
- Well-preserved or exaggerated arterial blood flow in the foot.
- Pedal pulses bounding, unless obscured by concurrent oedema.
- Patients with chronic deformities can develop limb-threatening ischaemia.

Initial clinical findings can resemble cellulitis, deep vein thrombosis or acute gout and can be mis-diagnosed as such.²⁰

Radiography and other imaging techniques can detect subtle changes consistent with CN.²⁰

✔ Testing for loss of sensation

There are two simple tests for peripheral neuropathy⁷:

- 10g monofilament is used to detect the presence of sensory neuropathy. It should be applied at various sites along the plantar aspect of the foot.
- Tuning fork – standard 128Hz – is used to test the ability to feel vibrations. A biothesiometer is a device that also helps assess the perception of vibration.

Other screening methods for diabetic peripheral neuropathy are ankle reflex testing, pinprick testing, light touch sensory testing (Ipswich touch test) or a pressure-specified sensory device. A test for temperature discrimination can be done with, for example, a Tip-therm examination^{21,22}.

Loss of protective sensation is a major component of nearly all DFUs and is associated with a seven-fold increase in risk of ulceration³.

✔ Testing for vascular status and oxygenation levels


- Palpation of peripheral pulses: femoral, popliteal and pedal (dorsalis pedis and posterior tibial) pulses⁷. The absence of both pedal pulses is an indicator of pedal vascular disease.
- Doppler ultrasound, Doppler waveform and ankle brachial pressure index (ABPI) may also be used⁷. Be aware that high ABPI is associated with arterial calcification in patients with diabetes²³. If the ABPI is measured as 1.3 or higher, further tests (e.g. toe-brachial index) should be performed or the patient should be referred for vascular assessment¹¹.
- Toe-brachial index (TBI)¹¹.
- Observation of discoloration (rubor) or venous refilling greater than five seconds on dependency may indicate poor arterial perfusion²⁴.
- Measurement of tissue oxygenation near the wound by transcutaneous oximetry (TcPO₂)⁷ or with medical hyperspectral imaging²⁵. Oxygen has a crucial role in wound healing, it is needed to generate the extra energy required for healing damaged tissue, driving tissue granulation and resistance against infection^{26,27}. It has also been proven that sustained oxygen at the wound site is vital for patients with non-healing wounds associated with peripheral arterial occlusive disease and DFUs²⁸. Therefore treatment with topical oxygen therapy (TOT) or hyperbaric oxygen therapy (HBOT) need to be considered. TcPO₂ can serve as a useful clinical tool for wound management and is the best currently approved surrogate for measuring oxygen levels in the wound bed²⁹⁻³².
- Where vascular issues and reduced blood supply are suspected, the patient should be referred for specialist vascular assessment¹¹.

✔ Examination of the wound and surrounding skin

A physical examination should determine^{7,8}:

- Whether the wound is predominantly neuropathic, ischaemic or neuroischaemic.
- Critical limb ischaemia (if ischaemic).
- Any musculoskeletal deformities.
- Size/depth/location of the wound.
- Tissue types present (colour/status of the wound bed):
 - Black/necrotic.
 - Yellow/slough.
 - Red/granulation.
 - Pink/epithelialisation.
- Exposed bones, tendons, joint capsules or orthopaedic implants.
- Signs of infection (See Identifying infection page 7).
- Odour: presence and nature.
- Local pain: e.g. location, type, cause, intensity and duration.
- Exudate: amount (high, moderate, low, none) colour and consistency and whether it is purulent.
- Status of the wound edge: e.g. callus, maceration, erythema, oedema, undermining/tracks/sinuses and raised edge.
- Condition of surrounding skin: e.g. maceration/excoriation, erythema, oedema or dry skin.

Is your team documenting wound size and status with digital photographs and/or apps? The placement of a paper ruler in the vicinity of the wound can help to indicate its size. For consistency, always measure in centimetres, listing in the order of length x width x depth.³³



A study has identified 3 factors associated with developing a foot infection: a previous amputation, loss of protective sensation and peripheral vascular disease (defined as any missing pedal pulsation or an ABPI of <0.8)³⁵.

✔ Identifying infection

Approximately 56% of DFUs become infected and about 20% of patients with an infected wound on the foot will undergo a lower extremity amputation³⁴. If infection is suspected, the DFU should be sampled after debridement for microbiological analysis and the result should be used to guide antibiotic selection¹⁵.

The diagnosis of diabetic foot infection (DFI) should be based on the presence of two or more of the following: local swelling or induration, erythema, local tenderness/pain, local warmth or purulent secretions¹⁵. Some DFIs may not exhibit these signs, especially in the case of patients who have peripheral neuropathy or limb ischemia¹⁵.

It is important to recognise the subtle signs of infection which may include just one of these signs above, combined with two local signs of infection (from the list below)⁸.

Additional or secondary signs, e.g.^{8,15}:

- Increased exudate
- Nonpurulent secretions
- Friable or discolored, granulation tissue
- Undermining of wound edges
- Malodour

DFI is classified into **mild** (superficial with minimal cellulitis), **moderate** (deeper or more extensive), or **severe**. In severe infections, fever or hypothermia, increased heart and respiratory rates, and high or low white cell counts may occur^{15,35,36}.

Other causes of an inflammatory response of the skin should be excluded (e.g. trauma, gout, acute Charcot neuro-osteoarthropathy, fracture, thrombosis, venous stasis)^{15,36}.

In case of an acute spreading infection, critical limb ischaemia, wet gangrene or an unexplained hot, red, swollen foot with or without the presence of pain, the patient urgently needs to be referred to the specialist foot care team⁷.

Osteomyelitis

Osteomyelitis – an infection in a bone – can be difficult to diagnose in the early stages. It should be considered as a potential complication of any infected, deep, or large foot ulcer, especially one that is chronic or overlies a bony prominence. A probe-to-bone (PTB) test should be done for any DFI with an open wound¹⁵. The National Institute for Health, Care and Excellence (NICE) in the United Kingdom recommend that if initial x-rays do not confirm the presence of osteomyelitis and suspicion remains high, consider magnetic resonance imaging (MRI)^{10,15}. The most definitive way to diagnose osteomyelitis is by the combined findings of culture and histology from a bone specimen obtained during deep debridement or by biopsy¹⁵.

Holistic foot ulcer management

Assessment of patients and their feet

1 Medical history

- Physical, physiological and psychosocial health

2 Feet inspection

- Callus, cracks
- Colour, erythema
- Temperature
- Dry skin
- Eczema
- Oedema of feet/lower legs
- Deformities e.g. Charcot foot (need for x-ray/MRI)
- Previous amputations
- Gangrene
- Inspecting nails and between the toes

3 Neuropathy

- **Motor neuropathy** (deformities)
- **Sensory neuropathy** (loss of sensation and vibration. Tests with 10g Monofilament and tuning fork)
- **Autonomic neuropathy** (dry skin, cracking skin, callus)

4 Vascular status and oxygenation levels

- Palpation of peripheral pulses: femoral, popliteal and pedal (dorsalis pedis and posterior tibial) pulses
- Doppler assessment and ABPI
- Toe-brachial index (TBI)
- Potential referral to a specialist for a full vascular assessment
- Consider oxygen assessment e.g. with transcutaneous oximetry (TcPO₂)

5 Wound and periwound

▶ **Infection:**
Local signs of infection can be: increased exudate, non-healing, malodour, friable or discoloured granulation tissue, redness, pain, heat and swelling. If osteomyelitis is suspected, or an active spreading infection, refer to a multidisciplinary footcare team immediately.

▶ **Wound bed, status/colour:**
– Black necrotic tissue
– Yellow slough
– Red granulation tissue, pink epithelialisation

▶ **Depth**

▶ **Exudate**
– Amount (none, low, moderate, high)
– Consistency/colour

- **Wound location**
- **Wound size (area/depth)**
- **Wound edge** (raised edge, undermining/tracks/ sinuses)
- **Surrounding skin** (maceration/excoriation, erythema, oedema)
- **Exposed bones, tendons, joint capsules or orthopaedic implants**
- **Pain** (location, frequency, cause, type, intensity and duration)
- **Odour** (presence and nature)

6 Classification

e.g. Wifl, University of Texas, Wagner, PEDIS or SINBAD

Goals of treatment, education and concordance with the patient

60-second Diabetic Foot Screen a Screening tool (2018).³⁷

Management of DFU⁸

A patient with a diabetic foot ulcer (DFU) or at risk of developing a DFU needs to be referred to a multidisciplinary footcare team (MDFT). They can provide with e.g.

- Offloading wound and risk areas with specialist foot wear.
- Full vascular assessment.
- Oedema treatment.
- Infection control and treatment.
- Wound debridement/cleansing and treatment recommendation.


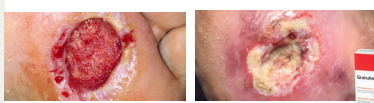

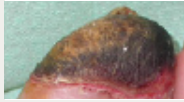
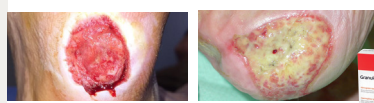




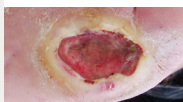
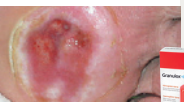






- Nutritional advice.
- Optimal diabetes control.
- **Remember:**
- Assess and manage pain (local and systemic) before dressing changes.
- Be aware of the arterial blood supply. If dry black necrosis – keep dry and refer for a full vascular assessment.
- Moisturize lower extremities and feet daily. Do not put lotion between toes.
- Educate on self-treatment for healthy feet.

For complete and updated assessment and management guidance please visit International Working Group on the Diabetic Foot (IWGDF) <https://iwgdfguidance.org>

These recommendations are aligned with the International best practice guidelines: IWGDF practical guidelines on the prevention and management of diabetic foot disease, 2019.

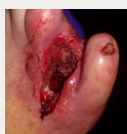ent in patients with diabetes

Mölnlycke dressing selection guide

	Requirement for antimicrobial*		No requirement for antimicrobial		
Infection					
Wound bed	Black dry Necrosis 	Red or Yellow  **Topical oxygen therapy with Granulox® 	Black dry Necrosis 	Red or Yellow  **Topical oxygen therapy with Granulox® 	
Depth	✓	Cavity  Superficial  **Topical oxygen therapy with Granulox® 	✓	Cavity  Superficial  **Topical oxygen therapy with Granulox® 	
Exudate level	 Mepilex® Transfer Ag	Cavity ✓ Superficial ✓	 Mepitel® One	Cavity ✓ Superficial ✓	
	>	Exufiber® Ag+ + Mepilex® Lite	Mepilex® Ag	Exufiber® + Mepilex® Lite	Mepilex® Lite or Mepilex® XT
	>	Exufiber® Ag+ + Mepilex® Border Flex	Mepilex® Border Ag	Exufiber® + Mepilex® XT or Mepilex® Border Flex	Mepilex® Border Flex
	>	Exufiber® Ag+ + Mextra® Superabsorbent	Mepilex® Transfer Ag + Mextra® Superabsorbent	Exufiber® + Mextra® Superabsorbent	Mepilex® Transfer + Mextra® Superabsorbent

If ulcer size has not reduced by more than 50% by 4 weeks reassess and refer to a MDFT or consider other/advanced technologies^{8,9,11}.

** Topical oxygen therapy (TOT) with Granulox® is suitable for patients at high risk of delayed wound healing³⁸.



* For infected DFUs (see picture), aggressive debridement, topical antiseptics and systemic antibiotics are generally recommended. Active spreading infection must be referred as a matter of urgency to a MDFT. Topical antimicrobial agents, e.g. in cleansers or dressings, may be used in combination with antibiotics to treat mild infections. Such dressings or cleansers may also be used alone to treat DFUs which are highly at risk of developing infections.^{7,8}

Be aware of systemic infection symptoms:

- Fever
- Rigour
- Chills
- Hypotension
- Multi-organ failure

Read more at:







www.mdcalc.com/sirs-sepsis-septic-shock-criteria

- Optimal wound management with provision of local treatment need to be supported with appropriate management of systemic disease, pressure offloading and debridement. Remember that surgical debridement is contraindicated if ischaemia is present¹¹
- Monitor at each dressing change and reassess regularly. Be sure that the dressing is compatible with shoes and other offloading therapies and can be accommodated without bulk and creasing
- If you need to cut the dressing, consider using non-bordered products
- For fixation, consider using Tubifast®
- If you need to dress a toe, consider using Mepitel® One or Mepilex® Lite for good conformability
- The choice of dressings must be based on local protocols and clinical judgement

Patient education for self-care

Educating your patients on proper foot care and periodic examinations can help prevent foot problems and ulceration. Education should be presented in a structured and organised manner; the aim is to enhance motivation and skills. Have your patients understood the messages? Are they motivated to act? Do they have sufficient self-care skills?

Here's a checklist to share with your patients, to help them keep their feet healthy³⁹.


-  **1. Take care of your diabetes and your health.** Maintenance of good blood glucose control can help reduce the risk of both developing neuropathy and circulation damage. If you have a foot problem, keeping your blood sugars well controlled can help the healing process.
-  **2. Check your feet every day.** Look at your bare feet for red spots, cuts, swelling and blisters. If you cannot see the bottoms of your feet, use a mirror or ask someone for help.
-  **3. Have your feet examined** for sensitivity and pulses at least annually by a professional (such as a podiatrist). If your clinician identifies your feet as being at risk for ulceration, you should be examined more often.
-  **4. Wash your feet every day** with lukewarm water. Dry them carefully, especially between toes.
-  **5. Keep your skin soft and smooth.** Rub a thin coat of skin lotion over the tops and bottoms of your feet, but not between your toes.
-  **6. Trim your toenails straight across** and file the edges with an emery board or nail file.
-  **7. Wear shoes and socks at all times.** Never walk barefoot. Wear comfortable shoes that fit well and protect your feet both indoor and outdoor. Check inside your shoes before wearing them. Make sure the lining is smooth and there are no objects inside. Change socks daily and use socks without constraining cuffs or seams (or with the seams inside out).
-  **8. Stay active to maintain healthy blood circulation.** Be active each day for example: walking, dancing, swimming, or going bike riding. Put your feet up when sitting. Two or three times per day, wiggle your toes and move your ankles up and down for five minutes. Don't cross your legs for long periods of time. Give up smoking, it can damage your circulation.
-  **9. Protect your feet from extreme temperatures.** Wear shoes at the beach or on hot pavements. Don't put your feet into hot water. Test water before putting your feet in. Never use hot-water bottles, heating pads, or electric blankets. You could burn your feet without realising it.
-  **10. Pick the right shoes.** Proper shoes are an important part of keeping your feet healthy. Buy your shoes in the late afternoon or evening, when feet are at their largest. Pick comfortable footwear with enough room for your toes. Avoid open-toed shoes. If you need more advice or help, consult an orthopaedic shoemaker.

Call or see your healthcare provider if you have cuts or breaks in the skin, or have an ingrown nail. Also, tell your healthcare provider if your foot changes colour, shape, or just feels different; for example, becomes less sensitive or hurts. If you have corns or calluses, your healthcare provider can trim them for you. Your healthcare provider can also trim your toenails if you cannot do so safely.




Dressing information

Mepitel® One



- Soft silicone wound contact layer
- For dry to highly exuding wounds
- Highly transparent for quick and easy wound inspection
- Can remain in place for up to 14 days depending on the wound condition⁴⁰
- Minimises skin damage and pain at dressing changes⁴⁰⁻⁴²

Mepilex® XT Mepilex® Ag



- Foam dressings with soft silicone wound contact layers with (Mepilex Ag) and without silver (Mepilex XT)
- For low to moderately exuding wounds, designed to maintain a moist wound environment
- Soft and conformable foam dressing
- Can easily be cut to size
- Mepilex XT can handle both low and high viscosity fluid⁴⁴
- Mepilex Ag kills wound-related pathogens within 30 minutes; and carries on doing so for up to 7 days *[in vitro studies]*⁴⁵
- Minimise skin damage and pain at dressing changes⁴³

Exufiber®



- Gelling fiber dressing
- Transforms into a gel that provide a moist wound environment^{53,54}
- High tensile strength to enable dressing removal in one piece⁵⁴
- Absorbs and retains exudate, blood and bacteria⁵⁴
- Soft and conformable which make it easy to apply⁵³

Exufiber® Ag+



- Gelling fibre dressing containing silver
- Transforms into a gel and softly conforms to the wound bed^{55,56}
- For moderately to highly exuding wounds
- The Hydrolock® Technology absorbs and locks in exudate, blood and bacteria. The high structural integrity enables one-piece dressing removal⁵⁷⁻⁶²
- Silver kills a broad range of pathogens *[in vitro]* and reduce biofilm, the antimicrobial effect is kept for up to seven days *[in vivo]*⁶³⁻⁶⁵
- Can easily be cut and used in cavities

Mextra® Superabsorbent



- Superabsorbent dressing with fluid-repellent backing
- For highly exuding wounds
- Superabsorbent particles for high absorption and retention⁶⁹
- Soft and conformable
- Fluid repellent backing layer protects against fluid strike-through

Mepilex® Lite



- Light foam dressing with soft silicone wound contact layer
- For non to low-exuding wounds; designed to maintain a moist wound environment
- Thin, soft, and highly conformable
- Can easily be cut to size
- Minimises pain and damage at dressing change⁴³

Mepilex® Border Flex




- All-in-one bordered foam dressing with flex cuts
- For moderately to highly exuding wounds; designed to maintain a moist wound environment
- Enables 360 degree stretch to enhance stay-on-ability and conformability⁴⁶⁻⁴⁹
- Contains superabsorbent fibres for high absorption and retention⁵⁰
- Minimise skin damage and pain at dressing changes^{43,50}

Mepilex® Border Ag



- All-in-one bordered foam dressing containing silver
- For moderately to highly exuding wounds; designed to maintain a moist wound environment
- Combines excellent exudate management properties with antimicrobial action^{51,52}
- Minimise skin damage and pain at dressing changes⁴³

Mepilex® Transfer Mepilex® Transfer Ag



- Exudate transfer dressings with (Mepilex Transfer Ag) and without silver (Mepilex Transfer)
- Effectively transfer exudate to a secondary layer⁶⁶
- Very thin and conformable foam for difficult-to-dress locations
- Can easily be cut to size
- Mepilex Transfer Ag inactivates a broad range of microorganisms *[in vitro studies]*⁶⁷
- Mepilex Transfer Ag combines a rapid antimicrobial effect within 30 min and a sustained effect up to 14 days *[in vitro studies]*⁶⁷
- Minimise skin damage and pain at dressing changes^{43,68}

Tubifast®



- Tubular retention bandage
- Holds dressings securely, without constriction or compression
- A variety of lengths are available
- Available in a range of quick reference, colour-coded sizes to fit everything from small limbs to adult trunks

Granulox®



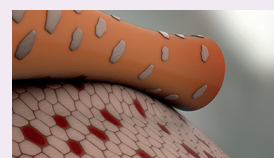
- Topical haemoglobin-based spray
- The haemoglobin spray acts by facilitating the diffusion of oxygen from the atmosphere into the wound bed
- Time to heal diabetic foot ulcers 50% shorter than with standard of care⁷⁰
- Granulox® is easy to handle and to apply

Proven choice for a better outcome

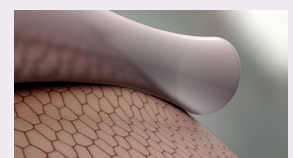SafetaC® is the original less-pain contact layer with silicone adhesion. We designed it to mould softly to skin without sticking to the moist wound⁷¹ – so you can remove it easily without damaging the skin⁷². That means less pain for your patients⁴³.

SafetaC also protects new tissue and intact skin – so wounds remain undisturbed to support faster natural healing^{41,42,73,74}. And it seals the wound margins to protect skin from damaging leaks and maceration^{75,76}. This combination of less pain⁴³ and less skin damage^{42,72-75,77} – to support faster healing^{41,42,73,74} – can also reduce the cost of treatment^{42,64,68}.

You can trust Mölnlycke® dressings with SafetaC, for better patient and economic outcomes.



Skin stripping occurs with traditional adhesive⁷²



No skin stripping occurs with SafetaC technology⁷²



Proving it every day

At Mölnlycke®, we deliver innovative solutions for managing wounds, improving surgical safety and efficiency and preventing pressure ulcers. Solutions that help achieve better outcomes and are backed by clinical and health-economic evidence.

In everything we do, we are guided by a single purpose: to help healthcare professionals perform at their best. And we're committed to proving it every day.

Mölnlycke would like to acknowledge Dr. Paul Chadwick for reviewing this guide.

Please note: This guide is not comprehensive and the reader should always refer to local guidelines.

References: 1. Armstrong, D.G., Boulton, A.J.M., Bus, S.A. Diabetic foot ulcers and their recurrence. *New Engl J Med* 2017;376:2367-75. 2. Rodrigues, B.T., Vangaveti, V.N., Malabu, U.H. Prevalence and risk factors for diabetic lower limb amputation: a clinic-based case control study. *J Diabetes Res* 2016; 5941957. Available at: <http://dx.doi.org/10.1155/2016/5941957> [Accessed 8 November 2018]. 3. Singh, N., Armstrong, D.G., Lipsky, B.A. Preventing foot ulcers in patients with diabetes. *JAMA* 2005;293(2):217-28. 4. Hinchliffe, R.J., Andros, G., Apelqvist, J., et al. A systematic review of the effectiveness of revascularization of the ulcerated foot in patients with diabetes and peripheral arterial disease. *Diabetes Metab Res Rev* 2012;28 (Supplement 1): 179-217. 5. Boulton, A.J.M. The pathway to foot ulceration in diabetes. *Med Clin N Am* 2013;97:775-90. 6. Pecoraro, R.E., Reiber, G.E., Burgess, E.M. Pathways to diabetic limb amputation. Basis for prevention. *Diabetes Care* 1990; 13(5): 513-21. 7. International Best Practice Guidelines. Wound Management in Diabetic Foot Ulcers. Wounds International 2013. Available at: <http://www.woundsinternational.com> [Accessed 8 November 2018]. 8. World Union of Wound Healing Societies (WUWHS). Florence Congress. Position Document. Local Management of Diabetic Foot Ulcers. Wounds International 2016. Available at: <http://www.woundsinternational.com> [Accessed 8 November 2018]. 9. Frykberg, R.G., Banks, J. Challenges in the treatment of chronic wounds. *Adv Wound Care (New Rochelle)* 2015;4:560-82. 10. National Institute for Health and Care Excellence. Diabetic foot problems: prevention and management. NICE guideline 19 2015. Available at: <https://www.nice.org.uk/guidance/ng19/diabetic-footproblems-prevention-and-management-pdf-183729829933> [Accessed 8 November 2018]. 11. Ousey, K., Chadwick, P., Jawien, A., et al. Identifying and treating foot ulcers in patients with diabetes: saving feet, legs and lives. *J Wound Care* 2018;27 (Suppl 5):S1-S52. 12. Wagner, R.W. The dysvascular foot: a system for diagnosis and treatment. *Foot Ankle* 1981;2(2):64-122. 13. Lavery, L.A., Armstrong, D.G., Harkless, L.B. Classification of diabetic foot wounds. *J Foot Ankle Surg* 1996;35:528-31. 14. Armstrong, D.G., Lavery, L.A., Harkless, L.B. Validation of a diabetic wound classification system. The contribution of depth, infection, and ischemia to risk of amputation. *Diabetes Care* 1998;21:855-9. 15. Lipsky, B., Berendt, A., Cornia, P.B. Infectious Diseases Society of America clinical practice guideline for the diagnosis and treatment of diabetic foot infections. *IDSA guidelines. Clin Infect Dis* 2012;54:132-73. 16. Ince, P., Abbas, Z.G., Lutale, J.K., et al. Use of the SINBAD classification system and score in comparing outcome of foot ulcer management on three continents. *Diabetes Care* 2008;31:964-67. 17. Mills, J.L., Conte, M.S., Armstrong D.G., et al. Society for Vascular Surgery Lower Extremity Guidelines Committee. The Society for Vascular Surgery Lower Extremity Threatened Limb Classification System: risk stratification based on wound, ischemia, and foot infection (WIFI). *J Vasc Surg* 2013;59(1), 220-34.e1-2. 18. Prompers, L., Huijberts, M., Apelqvist, J., et al. High prevalence of ischaemia, infection and serious comorbidity in patients with diabetic foot disease in Eu-rop. Baseline results from the Eurodiat study. *Diabetologica* 2007;50(1):18-25. 19. Apelqvist, J., Elgzry, T., Larsson, J., et al. Factors related to outcome of neuroischaemic / ischemic foot ulcer in diabetic patients. *J Vasc Surg* 2011;53:1582-8. 20. Rogers, L.C., Frykberg, R.G., Armstrong, D.G. The Charcot Foot in Diabetes. *Diabetes Care* 2011;34:2123-9. 21. Craig, A.B., Strauss, M.B., Daniller, A., Miller, S.S. Foot sensation testing in the patient with diabetes: introduction of the quick & easy assessment tool. *Wounds* 2014;26(8):221-231. 22. Viswanathan, V., Snehalatha, C., Seena, R., Ramachandran, A. Early recognition of diabetic neuropathy: evaluation of a simple outpatient procedure using thermal perception. *Postgrad Med J* 2002;78:541-542. 23. Bailey, M.A., Griffin, K.J., Scott, D.J.A. Clinical assessment of patients with peripheral arterial disease. *Semin Intervent Radiol* 2014;31:292-9. 24. LoGerfo, F.W., Coffman, J.D. Current concepts. Vascular and microvascular disease of the foot in diabetes. Implications for foot care. *New Engl J Med* 1984;311:1615-19. 25. Lua, G., Fei, B. Medical hyperspectral imaging: a review. *Biomed Opt. Opt. Lett.* 2014;19(1):010901. 26. Sen, C.K. Wound healing essentials: let there be oxygen. *Wound Repair Regen* 2009;17(1):1-18. 27. Gottrup, F. Oxygen in wound healing and infection. *Wound J Surg* 2004;28(3):312-5. 28. Dissemond, J., Kroger, K., Storck, M., et al. Topical oxygen wound therapies for chronic wounds: a review. *J Wound Care* 2015;24(2):53-63. 29. Ruangsetakit, C., Chinsakchai, K., Mahawongkajit, P. et al [2010] Transcutaneous oxygen tension: a useful predictor of ulcer healing in critical limb ischaemia. *J Wound Care* 2010;19(5):202-6. 30. Arsenault, K.A., Al-Otaibi, A., Devreux, P.J. et al. The use of transcutaneous oximetry to predict healing complications of lower limb amputations. *Eur J Vasc Endovasc Surg* 2012;43:329-36. 31. Zulec, M. Transcutaneous oximetry – between theory and practice. *Acta Med Croatica* 2014;68 Suppl 1:S59-S61. 32. Gottrup, F., Dissemond, J., Baines, et al. Use of oxygen therapies in wound healing, with special focus on topical and hyperbaric oxygen treatment. *J Wound Care*, 2017;26(5), Suppl, S1-S42. 33. Nicholls, E. Wound assessment part 1: how to measure a wound. *Wound Essentials* 2015;10:51-5. 34. Wu, S.C., Driver, V.R., Wrobel, J.S., Armstrong, D.G. Foot ulcers in the diabetic patient, prevention and treatment. *Vasc Health Risk Manage* 2007;3:65-76. 35. Peters, E.J., Lavery, L.A., Armstrong, D.G. Diabetic lower extremity infection: influence of physical, psychological, and social factors. *J Diabetes Complications* 2005;19:107-12. 36. Lipsky BA, Aragon-Sanchez J, Diggle M, et al. IWDGF Guidance on the diagnosis and management of foot infections in persons with diabetes. International Working Group on the Diabetic Foot. 2015. 37. INLOW's 60-second Diabetic Foot Screen. Screening tool. Canadian Association of Wound Care. www.cawc.net. 2011. 38. Chadwick, P.M., McCordle, J., Luxmi, M., et al. Appropriate use of topical haemoglobin in chronic wound management: consensus recommendations. *Wounds UK* 2015;EWMA Special: 30-35. 39. National Institute of Diabetes and Digestive and Kidney Diseases. Preventing Diabetes Problems. Diabetes and Foot Problems. Available at: <https://www.niddk.nih.gov/health-information/diabetes/overview/preventing-problems/foot-problems> [Accessed 8 November 2018]. 40. Patton, M.L., Mullins, R.F., Smith, D., Korentager, R. An open, prospective, randomized pilot investigation evaluating pain with the use of a soft silicone wound contact layer vs bridal veil and staples on split thickness skin grafts as a primary dressing. *J Burn Care Res* 2013;34:674-81. 41. David, F., Wutze, J.-L., Breton, N., et al. A randomised, controlled, non-inferiority trial comparing the performance of a soft silicone-coated wound contact layer (Mepitel One) with a lipidocolloid wound contact layer (UrگوTul) in the treatment of acute wounds. *Int Wound J* 2017 doi:10.1111/iwj.12853. 42. Gotschall, C.S., Morrison, M.J., Eichelberger, M.R. Prospective, randomized study of the efficacy of Mepitel on children with partial-thickness scalds. *J Burn Care Rehabil* 1998;19:279-83. 43. White, R. A multinational survey of the assessment of pain when removing dressings. *Wounds UK* 2008;4:14-22. 44. Mölnlycke Health Care data on file, report 20160105-002. 45. Chadwick, P., Taherinejad, F., Hamberg, K., Waring, M. Clinical and scientific data on a silver-containing soft-silicone foam dressing: an overview. *J Wound Care* 2009;18:483-91. 46. ProDerm study report 16.0180-23. Assessment of Wearing Properties of Wound Dressings on the Knees. Data on file. 47. ProDerm study report 16.0180-23. Assessment of Wearing Properties of Wound Dressings on the Elbows. Data on file. 48. ALTEN Finite Element Modelling simulation. Laboratory report no. PD-530246. 49. Haycocks, S., Chadwick, P., Davies, P. Case series: Mepilex Border Comfort in the treatment of diabetic foot ulcers with exudate. *Diabetic Foot Journal* 2018;21:265-71. 50. External test lab report SMTL15/4863/2. 51. External lab report: NAMS 09C 29253 01/09C 29253 02. 52. Kles C.L., Murrah, C.P., Smith, K., et al. Achieving and sustaining zero. Preventing surgical site infections after isolated coronary artery bypass with saphenous vein harvest through implementation of a staff-driven quality improvement process. *Dimensions Crit Care Nurs* 2015;34:265-72. 53. Smet, S., Beele, H., Sains, L., Suijs, E., Henrick, B. Open, noncomparative, multi-centre post market clinical follow-up investigation to evaluate performance and safety on pressure ulcers when using a gelling fibre dressing as intend-ed. Poster Presentation at European Pressure Ulcer Advisory Panel Confer-ence, 2015, Ghent, Belgium. 54. Chadwick P, McCordle J. Open, non-comparative, multicentre post clinical study of the performance and safety of a gelling fibre wound dressing on diabetic foot ulcers. *J Wound Care* 2016;25:290-300. 55. Davies P, McCarty S. An in-use product evaluation of a gelling fibre dressing in wound management. E-poster presentation at Wounds UK Conference, 2017, Harrogate, United Kingdom. 56. Lev-Tov et al. An interim analysis of clinical investigation to evaluate exudate management and comfort of use of an antimicrobial gelling fibre dressing* in medium to highly exudative wounds. Poster presented at the Symposium of Advanced Wound Care, Fall meeting 2018, Las Vegas, NV, USA. 57. Mölnlycke Health Care Laboratory Report PD-521248 [unpublished]. 58. Mölnlycke Health Care Laboratory Report PD-556978 [unpublished]. 59. Mölnlycke Health Care Laboratory Report PD-520425 [unpublished]. 60. Mölnlycke Health Care Laboratory Report PD- 521232 [unpublished]. 61. Mölnlycke Health Care Laboratory Report PD- 522900 [unpublished]. 62. Mölnlycke Health Care Laboratory Report PD- 521245 [unpublished]. 63. Hamberg K et al. Antimicrobial effect of a new silver-containing gelling fibre dressing against common wound pathogens. Poster presented at the Symposium on Advanced Wound Care Spring meeting/ Wound Healing Society (WHS) Annual Meeting 2017, Apr 05-09, 2017, San Diego, CA, USA. 64. Gil J et al. 2017. Evaluation of a Gelling Fiber Dressing with Silver to Eliminate MRSA Biofilm Infections and Enhance the Healing. Poster presented at the Symposium on Advanced Wound Care Spring meeting/ Wound Healing Society (WHS) Annual Meeting 2017, Apr 05-09, 2017, San Diego, CA, USA. 65. Valdes et al. 2017. Evaluation of a Gelling Fiber Dressing with Silver to Eliminate P. a. Biofilm Infections and Enhance the Healing. Poster presented at the Symposium on Advanced Wound Care Spring meeting/Wound Healing Society (WHS) Annual Meeting 2017, Apr 05-09, 2017, San Diego, CA, USA. 66. Grocott Patricia Clinical investigation Mepilex® Transfer. Clinical Investigation of a silicone dressing in product development phase in the palliative management of patients with pressure sores and malignant wounds, study id MIN101 UK, London UK,2000. 67. External lab report; NAMS 11C_ 51788_ 01. 68. Meuleneire, F. Management of diabetic foot ulcers using dressings with Safetac: a review of case studies. *Wounds UK* 2008;4:16-30. 69. Tickle, J., Fletcher, J. Mextra Superabsorbent made easy. *Wounds UK* 2012;8: 1-4. 70. Hunt SD, Elg F. Clinical effectiveness of hemoglobin spray (Granulox®) as adjunctive therapy in the treatment of chronic diabetic foot ulcers. *Diabetic Foot & Ankle* 2016;7:33101. 71. White R. Evidence for atraumatic soft silicone wound dressing use. *Wounds UK* 2005;1(3):104-109. 72. Waring, M., Biefeldt, S., Matzold, K.P., Butcher, M. An evaluation of the skin stripping of wound dressing adhesives. *J Wound Care* 2011;20:412-22. 73. Silverstein, P., Heimbach, D., Meites, H., et al. An open, parallel, randomized, comparative, multicenter study to evaluate the cost-effectiveness, performance, tolerance, and safety of a silver-containing soft silicone foam dressing (intervention) vs silver sulfadiazine cream. *J Burn Care Res* 2011;32:617-26. 74. Gee Kee, E.L., Kimble, R.M., Cuttle, L., Khan, A., Stockton, K.A. Randomized controlled trial of three burns dressings for partial thickness burns in children. *Burns* 2015;41:946-55. 75. Meaume, S., Van De Looerbosch, B., Heyman, H., Romanelli, M., Ciangherotti, A., Charpin, S. A study to compare a new self-adherent soft silicone dressing with a self-adherent polymer dressing in stage II pressure ulcers. *Ostomy Wound Manage* 2003; 49 (9): 44-51. 76. Wiberg, A.-B., Feil, F., Daun, E.-K. Preventing maceration with a soft silicone dressing: in-vitro evaluation. Poster presentation at the 3rd Congress of the World Union of Wound Healing Societies, Toronto, Canada, 2008. 77. Bredow, J., Hoffmann, K., Hellmich, M., Eysel, P., Zarghooni, K. Randomized clinical trial to evaluate performance of flexible self-adherent absorbent dressing coated with silicone layer after hip, knee or spinal surgery in comparison to standard wound dressing. Poster presentation at the 5th Congress of the World Union of Wound Healing Societies, Florence, Italy, 2016.

Find out more at www.molnlycke.com

Mölnlycke Health Care AB, Box 13080, Gamléstadsvägen 3C, SE-402 52 Göteborg, Sweden. Phone +46 31 722 30 00. The Mölnlycke, Mepilex, Mextra, Tubifast, Exufiber, Epaderm, Mepitel, TwoWay Stretch, Granulox and Safetac trademarks, names and logotypes are registered globally to one or more of the Mölnlycke Health Care group of companies. © 2019 Mölnlycke Health Care AB. All rights reserved. HQIM001160

